



Journal of Anatomical Sciences

Email:anatomicaljournal@gmail.com

J Anat Sci 12 (1)

Evaluation of antifertility effects of short-term administration of Africa Star Apple (*Chrysophyllum albidum*) on ovary of female Sprague-Dawley rats.

^{1*}Idaguko CA, ²Bakare AA, ³Ubeng EG and ⁴Nwakanma AA

¹Department of Anatomy, Faculty of Basic Medical Sciences. Edo University Iyamho, Edo State, Nigeria.

²Department of Anatomy, Faculty of Basic Medical Sciences. University of Lagos. Lagos State, Nigeria

³Department of Anatomy, Faculty of Basic Medical Sciences, Madonna University. Elele. Rivers State, Nigeria.

⁴Department of Anatomy, Faculty of Basic Medical Sciences, Chukwuemeka Odomegwu Ojukwu University, Uli Anambra state. Nigeria.

Corresponding Author: Idaguko CA

E-mail: annachi67@yahoo.com; + 234-805-491-9134.

ABSTRACT

Chrysophyllum albidum leave is one of the common folk medicinal plants used by some rural people in Nigeria. Its effects were study on sex hormones and the histology of the ovary of adult Sprague- Dawley rat. Fifteen female rats of 120-150g were used. The rats were grouped into three of five each. Group A was given distilled water, groups B and C received 250 and 500 mg/kg body weight of ethanolic leaf extract of *C. albidum* orally daily for 14 days respectively. Blood were collected for hormonal assays; the ovaries were excised and prepared histologically. A significant dose dependent ($P>0.05$) decreased in progesterone, estrogen, luteinizing hormone and FSH levels in all the treated groups were observed. Histologically, group B ovary had primary and secondary follicles while group C had atretic follicles, arrests at different phases of follicular development and in the medulla the vessels are not well defined. The weight of the heart, spleen, kidneys and pancreas of the rats were not affected. However, a significant decrease ($P < 0.05$) in the ovarian weight and increase in the weight of the liver in the treated groups when compared to the control was observed. *C. albidum* could retard folliculogenesis and delay ovarian follicle maturation. It is therefore; recommended to use it with caution if there is a reproductive issues.

Key Words: *Chrysophyllum albidum*, antifertility, hormones, ovary, histology.

INTRODUCTION

The rural populations have used plants to cure disease and relieve pain in the primary health care system for many years due to its availability, affordability, effectiveness, high acceptance and better compatibility^{1,2}. However, there are issues about the unplanned negative outcomes of these plants especially on the reproductive function. The reproductive system of the female is more complicated and more prone to be affected by external factors. Exposure of the reproductive system of the female to factors such as; drugs, life style, heavy metals, toxicants, organic solvent and ionizing radiation could lead to functional alterations^{3,4}.

Some medicinal herbs and plant-derived products have been known to have antifertility effect through alteration of the hypothalamo pituitary-gonadal axis or direct actions on reproductive hormones which have led to inhibition of ovarian steroidogenesis⁵. Some of these plants have been showed to be effective contraceptives for both females and males⁶. Hence, these plants used as contraceptive agent and research have confirmed the various mechanism of actions which includes; modulation and decrease secretion of

luteinizing hormone and follicle stimulating hormone, delay follicles maturation and ovulation, inhibition of developmental processes of the ovum and endometrium, impede implantation and abortifacient effects^{7,8}. *Cnidocolous aconitifolius*, *Quassia amara*, and *Asparagus africanus*, are few among natural plants that have been found to contain ant-fertility compounds and provide assurance for safe and effective contraceptive suitable for both males and female^{9,10,11}.

Moreover, some herbal plants have also been commonly used to improve or regulate female fertility¹². Natural plant products have been used to stimulate the pituitary gland to response to the gonadotropin releasing hormone secreted by the hypothalamus, enhance pulsatile release of LH and FSH, induced ovulation, stimulate the secretion of steroid hormones, possessed progesteronic and estrogenic effects^{13,14}.

Chrysophyllum albidum (*C. albidum*), is a medicinal plant that belongs to the botanical family Sapotacea. The plant is popularly known as Africa star apple, it is widely distributed across greater part of West Africa. It is used by traditional practitioners in Nigeria to cure

various ailments such as, dental decay, cough, yellow fever and malaria. Other uses of this plant, include treating; stomach-ache, skin rash and often watery bowel ^{15,16}. Scientist have reported its antimicrobial, antiplatelet, anti-nociceptive, antidiabetic, antioxidant and antifertility activities ^{17,16,18,19,20,21}.

Despite the many uses of *C. albidum*, its short term effects on the histology of the ovary and the reproductive hormones in female are not known. Indeed, this research aims at finding some scientific basis of the effects of short term administration of ethanolic leaf extract of *C. albidum*, on reproductive hormones and ovary in Sprague-Dawley rats.

MATERIALS AND METHODS

Animals: Fifteen female rats ten weeks old, weighing between 120-150g, were obtained from the animal facility of the Anatomy Department, University of Port Harcourt, Rivers State. The animals were allowed to acclimatize for two weeks and were kept in appropriate cages with wired open tops at constant temperature of 21±2°C, with an alternate 12-hour light and dark period. The animals were fed with rat pellet diet and provided with water *ad libitum*. The animals were treated humanely in line with the instruction of the Guide for the Care and Use of Laboratory Animals ²².

Plant materials: Leaves were harvested from a garden around the Madonna University, Rivers State Nigeria. It was authenticated at the Department of Botany, University of Lagos, Lagos State and identified as *C. albidum*. It was issued with a collector number LUH-7458, a sample of this was kept for future references.

Extraction of Leaf Extracts: The *C. albidum* extract was prepared using the method described by ²³, using running tap water, the leaves were washed and was dried under direct sunlight for a total of 14 days. The leaves were ground into powder using electric blender. Total of 790g of pulverized leave was put into a clean transparent bucket and soaked in 2.4 liters of 95 % ethanol for 24 hours. The mixture was stirred vigorously using a stirrer to allow for complete extraction. The resulting mixture was rapidly sieved using a porcelain cloth and then it was sieved again using Whatman No.1 filter paper. Furthermore, it was concentrated using a rotary evaporator at 50 °C (BUCHIR-215 Switzerland). The filtrate obtained was kept in a beaker and placed in the water bath (40°C) for it to be concentrated by evaporation. The extract was stored at 4° C in a refrigerator till further use.

Acute Toxicity Test: Twenty rats were randomized into five groups of four rats each. The rats in group 1 were treated with 500 mg/kg b. wt. of *C. albidum* extract. Similarly, animals in groups 2, 3 and 4 were treated with 1000, 1500 and 2000 mg/kg b. wt. of *C. albidum* respectively. The control group 5 received normal saline. The groups were observed for any signs of toxicity and general behavior was also noted for 24

hours ²⁴.

Grouping of Rats: Animals were assigned into three groups; A, B and C of five rats in each group with approximately equal mean body weight. Group A (control) received distilled water, while group B and C received 250 and 500 mg/kg b. wt. orally of *C. albidum* for 14 days respectively. The weights of the animals were weighed using Camry weighing balance (model JI801170752 China).

Collection of samples: Animals were sacrificed a day after the last administration of extract by using diethyl ether anesthesia. The blood samples were collected through cardiac puncture using a 22-19 mm gauge needle. Thereafter, it was transferred into an EDTA bottle (Ethylene Diamine Tetra- acetic) and was kept for 10 minutes to clot after which the EDTA bottles were placed in a centrifuge and centrifuged for 3000 rpm for 10 minutes. The serums obtained were aspirated using Pasteur pipettes into sample bottles and used for the hormonal assays.

Organ collection: After sacrifice, the ovaries, heart, kidneys, pancreas, spleen and liver were collected in Petri dish containing 0.9% normal saline. The organs were trimmed and cleared of adherent tissues before they were weighed with Mettler Toledo electronic weighing balance (model AL 204 Switzerland) with a capacity of 0.1 to 1000g.

Hormonal assay: The total serum luteinizing hormone (LH), progesterone (Prog), follicle stimulating hormone (FSH) and estrogen (E) concentration in control and treated groups were assayed using enzyme-linked Immuno-adsorbent assay (ELISA) kits with their respective catalogue numbers: (FSH) EIA-4K4L9, (LH) EIA-6K119, (Prog) EIA-48K318 and (E) EIA-49K3D9 supplied by Lemaco Investment Limited Nigeria. The instructions of the manufacturer was followed for the analysis as described by the kit producers. The assays employed competitive inhibition enzyme immunoassay technique using enzyme immunoassay ELISA kits. Every other reagents used were of analytical grade.

Histological studies: Through an abdomino-pelvic incision, the ovaries were removed, cleared of exogenous tissues and weighed using an electronic weighing balance before being fixed in bouin's fluid for 48 hours at room temperature for histological procedures. Other organs such as; heart, spleen, liver, kidney and pancreas were also removed and weighed. The ovary specimen was transferred into ascending grades of alcohol for dehydration. The tissues were treated by clearing in xylene for one and half hours and they were embedded in paraffin wax. Tissue sections of 5µ in thickness were cut from each paraffin block using microtome. The tissue section was stained with Haematoxylin and Eosin (H & E) stain by the standard method for light microscopic (histological)

examination.

Statistical analysis: Data obtained from this study was analyzed using GraphPad Prism software, version 5.0 (GraphPad Software, La Jolla, CA, USA). Analysis of variance (ANOVA) was done followed by Bonferroni post-test. Statistical significant level was considered at $P < 0.05$ and the results obtained were represented as Mean \pm SD (n = 5).

RESULTS

Changes in body and organ weights: The mean body weights of the groups A (134.67+ 6.7), B (133.4+ 7.0) and C (133.98+10.0) were similar at the beginning of

the experiment. Initially, the administration of the ethanolic extract of *C. albidum* at 250 and 500 mg/kg b. w gain weight at a slower rate than the control group during the experiment. However, on day 14 of the treatment, the rats administered the extract of *C. albidum* had significantly increased in body weight ($P < 0.05$) when compared to the control group (Figure1). There were no significant differences in the weights of the heart, liver, kidney, spleen, and pancreas treated with 250 and 500 mg/kg of ethanolic extract of *C. albidum* after 14-day experimental period. The mean weight of the ovarian-treated groups when compared to control (group A) showed a statistically significant ($P < 0.05$) ovarian weight loss (Table 1).

Table 1: Effect of ethanol leaf extract of *C. albidum* on the mean organ weight of female rats

Organs (g)	Group 1 (Control)	Group 2 (250 mg/kg <i>C. albidum</i>)	Group 3 (500 mg/kg <i>C. albidum</i>)
Heart	0.43 \pm 0.04	0.45 \pm 0.03	0.45 \pm 0.08
Liver	5.30 \pm 0.33	6.2 \pm 0.34*	7.10 \pm 0.43*
Pancreas	0.42 \pm 0.05	0.43 \pm 0.04	0.44 \pm 0.19
Spleen	0.76 \pm 0.09	0.77 \pm 0.12	0.78 \pm 0.05
Ovary	0.54 \pm 0.01	0.45 \pm 0.05*	0.41 \pm 0.13*
Kidney	0.39 \pm 0.04	0.36 \pm 0.04	0.35 \pm 0.20

Values expressed mean \pm SD (n=5)

Ovary * $P < 0.05$ when compared to the control

Liver * $P < 0.05$ when compared to the control

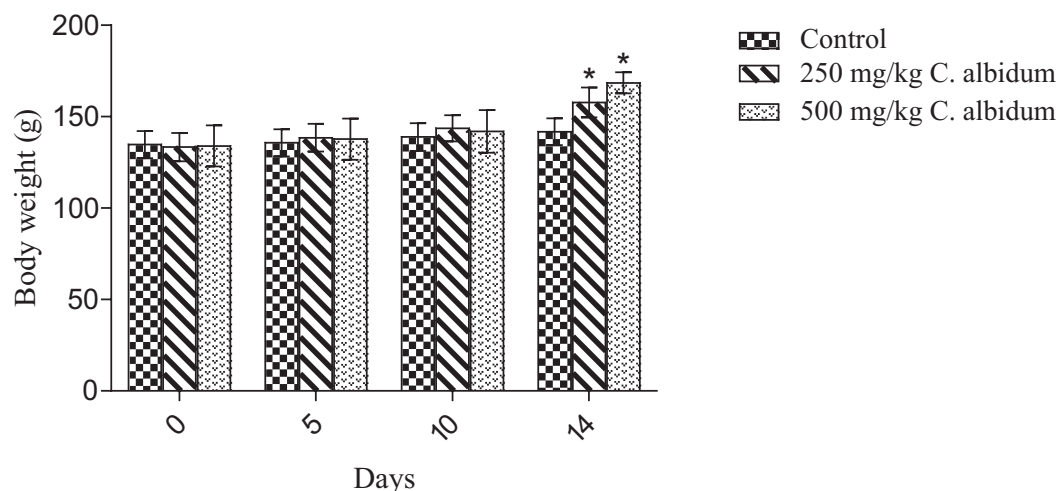


Figure 1: Mean body weight of rats in the group1 (control), group 2 (250 mg/kg *C. albidum*) and group 3 (500 mg/kg *C. albidum*). Data represent the mean \pm SD. (n = 5 for each group). * $P < 0.05$ when compared with the control.

Changes in the hormones: Ethanolic leave extract of *C. albidum* had effects on sex hormones of the treated groups such that the serum follicles stimulating hormones, luteinizing hormones, progesterone and estrogen levels were significantly decreased ($P < 0.05$) as compared to the control group (Figures 2: 2a, 2b, 2c, and 2d respectively).

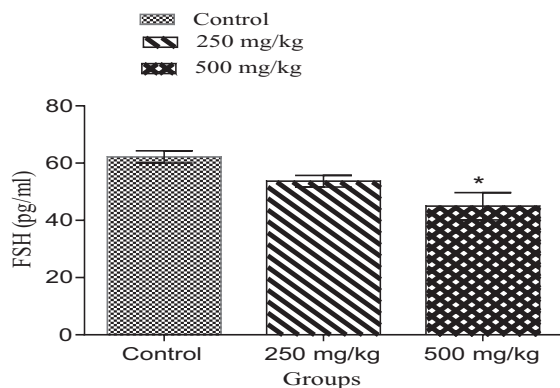


Figure 2a: FSH level in the group1 (control), group 2 (250 mg/kg *C. albidum*) and group 3 (500 mg/kg *C. albidum*). Data represent the mean \pm SD. (n = 5 for each group). * $P < 0.05$ when compared with the control.

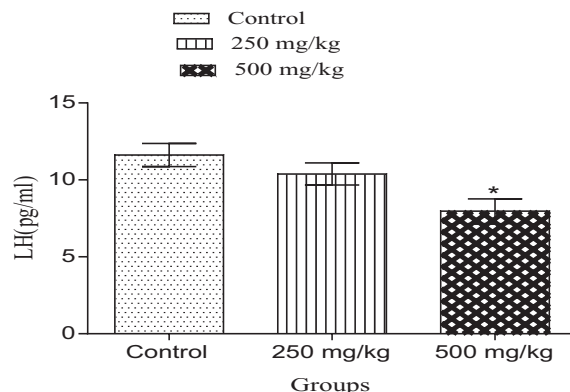


Figure 2b: LH level in the group1 (control), group 2 (250 mg/kg *C. albidum*) and group 3 (500 mg/kg *C. albidum*). Data represent the mean \pm SD. (n = 5 for each group). * $P < 0.05$ when compared with the control.

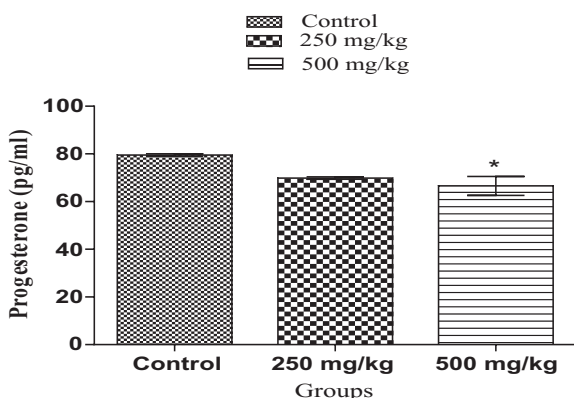


Figure 2c: Progesterone level in group1 (control), group 2 (250 mg/kg *C. albidum*) and group 3 (500 mg/kg *C. albidum*). Data represent the mean \pm SD. (n = 5 for each group). * $P < 0.05$ when compared with the control.

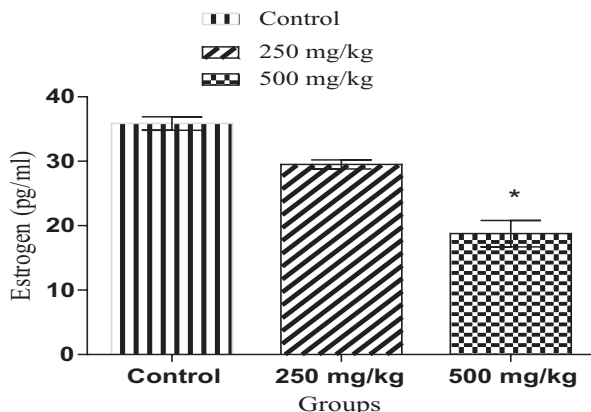


Figure 2d: Estrogen level in the group1 (control), group 2 (250 mg/kg *C. albidum*) and group 3 (500 mg/kg *C. albidum*). Data represent the mean \pm SD. (n = 5 for each group). * $P < 0.05$ when compared with the control.

Effects on the Histology of the Ovary: In the cortex of the control group, a mature graafian follicle is seen with a characteristic single fluid filled cavity (antrum) and granulosa cells distributed into the cumulus oophorus, membranous granulosa and corona radiata cells. There is corpus luteum in the cortex which shows evidence of recent ovulation (follicular remnant that secretes progesterone, the pregnancy hormone for the maintenance and protection of pregnancy if implantation occurs and if otherwise it will degenerate into a scar tissue). Also, there are follicles in the primary and secondary stages of development which will further develop into mature follicles in the subsequent cycle. In the region of the medulla, there are well

defined vasculatures (Figure 3a). Also, at the dose of 250 mg/kg a number of primary and secondary follicles are seen and this shows that the folliculogenesis is initiated. However, a number of atretic follicles were seen in the cortical region which shows that there have been damaging effects in the ovary. In the medulla region, there are well defined vasculatures which project the hope for further growth and development of the immature follicles (Figure 3b). Furthermore, at the dose of 500mg/kg, there was a number of atretic follicles in the cortical region; also an arrests at different levels of follicular development and the vessels are not well defined in the medulla (Figure 3c).

Figure 3: Effects of *C. albidum* on histology of the ovary

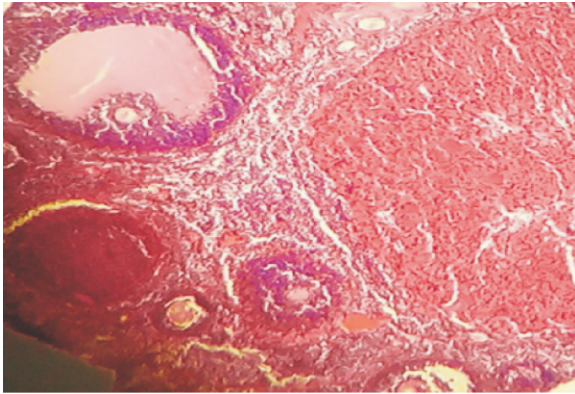


Figure 3a: The ovarian cross-section from a normal rat showing growing follicles at different stages; primary follicles, secondary and tertiary follicles and whorled stroma containing blood vessels (H and E x 100)

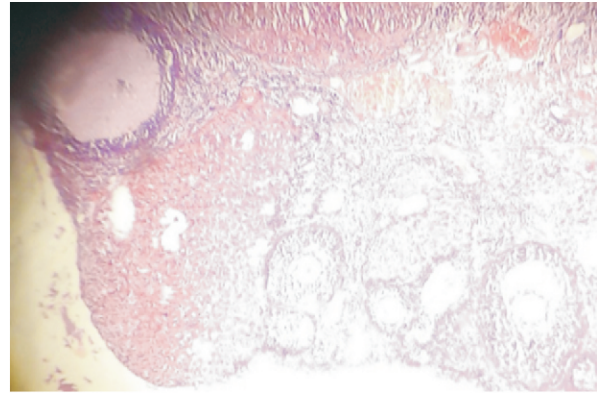


Figure 3b: Ovarian cross-section from a rat treated with 250 mg/kg of ethanolic leaf extract of *C. albidum* showing primary and secondary follicles, atretic follicles, vacuolization (H and E x 100)

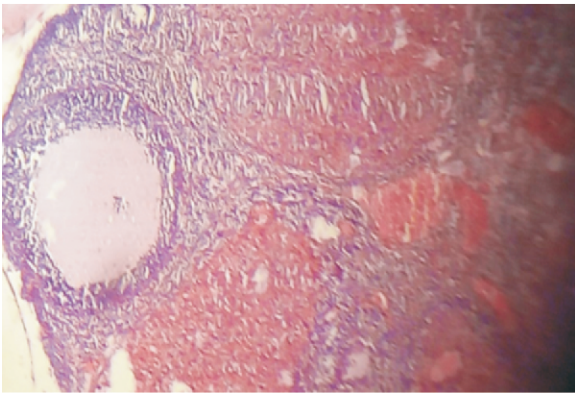


Figure 3c: The ovarian cross-section from a rat treated with 500 mg/kg ethanolic leaf extract of *C. albidum* showing atretic follicles (H and E x 100)

DISCUSSION

Body weight have a significant role in the control and secretion of gonadotrophin; and its role in steady cyclic function have also been reported²⁵. Hence, the adverse effect of *C. albidum* on endocrine functions was not foremost a function of the body weight as observed in the study. The increase in the body weight are consistent with another study by²⁶. Furthermore, the weight increase by *C. albidum* appeared to occur in a dose-dependent manner. However, the non-significant effect of *C. albidum* on the weights of the kidney, pancreas, spleen and heart of the rats is a sign that the extract did not have negative effect on the size of these organs; this observation is also in agreement with the work done by¹⁸. The significant increase in the liver as seen with *C. albidum* may be due to increase in the working capacity of the organ²⁷. However, a significantly decreased in the ovarian weights of the *C. albidum* treated groups was observed and this reduction appeared to occur in a dose-dependent form. Hence, the decrease in ovarian weight could probably be as a result of decreased estrogen level.

Phytochemical screening of plants extract has unveiled many substances. However, some of these substances are harmful and may act directly on the reproductive organs or influence the hypothalamus or/and pituitary gland^{28,29}. Phytochemical analysis of *C. albidum* leave extract have shown the following constituents are present; tannins, alkaloids, flavonoids, saponins, anthraquinones, steroids, cardiac glycosides, terpenoids and cardenolides³⁰. However, this plants are also used as contraceptive and the sites of activity of these plants in females includes the hypothalamus, the anterior pituitary gland, the ovary, the oviduct, the uterus and the vagina¹². The disrupting effect of various plant extracts on ovarian folliculogenesis have been reported since steroidogenesis and folliculogenesis takes place in the ovary^{31,32,33}.

The hypothalamus via Gonadotropin-releasing hormone control the changes that happens in the ovary. This hormone leads to the release of follicle stimulating hormone and luteinizing hormone by the pituitary

gland³⁴. Follicle stimulating hormone is of high importance for gonadal (growth and maturation) and sex cell production³⁵. It induces the growth and maturation of the ovarian follicles by acting on the receptors, located on the granulosa cells³⁶. Luteinizing hormone induces the secretion of sex hormones from the gonads. Therefore, a surge of luteinizing hormone release during the pre-ovulatory periods results in ovulation of mature follicles and also LH controls progesterone release from the corpus luteum for the maintenance of pregnancy³⁷. Hence, any disruption in the secretion of LH may trigger inhibiting of folliculogenesis, thereby affecting ovulation³⁸.

The extract was observed to reduce the levels of FSH, LH, progesterone and estrogen in the serum. Therefore, the inhibitory effect of *C. albidum* extract as observed could be due to the presence of flavonoids and alkaloids that have been reported to decrease the levels of LH, FSH and estradiol³⁹. Hence, it could be that *C. albidum* have effect on the anterior pituitary gland, resulting in the negative feedback on the pulsatile frequency of gonadotropic releasing hormone that are secreted by the hypothalamic-hypophyseal portal vessel. Thus, the FSH prevent further follicles from developing by inhibiting increase in the level of estrogen. In addition, the decrease in progesterone level and absence of estrogen positive feedback on LH secreted prevent LH surge⁴⁰.

The significant structural alterations in the photomicrograph of the ovary of the rats treated with *C. albidum* when compared with the control further support the possible deleterious effect of *C. albidum*. At a lower dose (250mg/kg), the primary and secondary follicles are present; suggesting that folliculogenesis was initiated. Nevertheless, atretic follicles were also present in the cortical region. In the histological photomicrograph of the higher dose of the extract (500mg/kg); the presence of atretic follicles in the cortical region and arrests at different phases of follicular development may be as a result of the decrease in estrogen levels. Since, it have been reported that estrogens suppress follicular atresia^{41,42}. Hence, at this dose folliculogenesis may be engendered as seen in the ovaries. Also, the alterations in the hormones and histology may result in the decrease in the ovarian weight. This result is in agreement with finding by⁴³ that reported that the active development of oocyte is influenced by steroidogenesis.

This showed that *C. albidum* probably act on the ovary via changes in the endocrine functions as presented with decreased estrogen level and consequent decrease in FSH and LH. Thus it is possible that phytochemicals present in *C. albidum* may possess anti-gonadotropic agents which may be responsible for the hormonal disorders seen in this study. In taking herbal medicines; the issue of its outcome on the reproductive system should be critically considered as procreation is a moral

relevance and right of all individuals. Hence, it is crucial to screen more herbs for their deleterious effect on reproductive function. The limitation of this study was the quantification of ovarian follicles and corpora luteum which were not reported.

CONCLUSION

This research showed that the ethanolic leaf extract of *C. albidum* have a negative influence on reproductive hormones and histomorphology of the ovary of the rats; and could be looked into as an alternative to oral contraceptive agents. However, it is suggested that female haven infertility or reproductive issues should refrain from taking *C. albidum*.

ETHICS OF STUDY

The Experiment was approved by Health Research Ethics Committee (HREC) of the College of Medicine, University of Lagos with ethical number CMUL/HREC/05/16/011.

CONFLICT OF INTEREST

All the authors declare that no conflicts of interests exist; and are fully responsible for the article write up

REFERENCES

1. Mohammed A, Ibrahim MA, Islam MS. African medicinal plants with antidiabetic potentials: A review. *Planta Medica* 2014; 80 (05): 354-77.
2. Mintah SO, Asafo-Agyei T, Archer MA, Junior PA, Boamah D, Kumadoh D, Appiah A, Ocloo A, Boakye YD, Agyare C. Medicinal plants for treatment of prevalent diseases. In *Pharmacognosy-Medicinal Plants* 2019. IntechOpen. doi: 10.5772/intechopen.82049.
3. Rzymiski P, Tomczyk K, Poniedzialek B, Opala T, Wilczak M. Impact of heavy metals on the female reproductive system. *Annals of agricultural and environmental medicine* 2015; 22 (2): 259-64.
4. Kumar S, Sharma A, Kshetrimayum C. Environmental & occupational exposure & female reproductive dysfunction. *The Indian Journal of Medical Research* 2019; 150 (6): 532-545.
5. Shibeshil W, Makonnen E, Debella A, Zerihun L. Phytochemical, contraceptive efficacy and safety evaluations of the methanolic leaves extract of *Achyranthes aspera* L. in rats. *Pharmacol* 2006; 3:217-224.
6. Daniyal M, Akram M. Antifertility activity of medicinal plants. *Journal of the Chinese Medical Association* 2015; 78 (7): 382-388.
7. Prakash AO, Saxena V, Shukla S, Mathur R. Contraceptive potency of *Pueraria tuberosa* DC and its hormonal status. *Acta europaea fertilitatis* 1985; 16 (1): 59-65
8. Brinker F. Inhibition of endocrine function by botanical agents, Antigonadotropic activity. *Br J Phytother* 1997; 4:123-145.
9. Yinusa R, Adeniran A, Oyeyipo PI, Omowumi FA. Reproductive activities of female albino rats treated with quassin, a bioactive triterpenoid from

- stem bark extract of *Quassia amara*. Nigerian Journal of Physiological Sciences 2010; 25(2): 95-102.
10. Shaik A, Yalavarthi PR, Bannoth CK. Role of Antifertility Medicinal Plants on Male & Female Reproduction. Journal of Complementary and Alternative Medical Research 2017; 3(2):1-22.
 11. El-Ishaq A, Alshawsh MA, Mun KS, Chik Z. Phytochemical screening and anti-implantation activity of *Asparagus africanus* root extract in female Sprague–Dawley rats. Revista Brasileira de Farmacognosia 2019; 29 (5): 621-30.
 12. Al-Snafi AE. Arabian medicinal plants affected female fertility-plant based review (part 1). IOSR Journal of Pharmacy 2018; 8(7): 46-62.
 13. Dalkin AC, Haisenleder DJ, Ortolano GA, Ellis TR, Marshall JC. The frequency of gonadotropin-releasing-hormone stimulation differentially regulates gonadotropin subunit messenger ribonucleic acid expression. Endocrinology 1989; 125 (2): 917-923.
 14. Grachev P, Goodman RL. The GnRH pulse generator. AIMS Medical Science 2016; 3(4):359-385. doi:10.3934/medsci.2016.4.359
 15. Adisa SA . Vitamin C, Protein and Mineral content of African Apple (*Chrysophyllum albidum*) in proceedings of the 18th Annual Conference of NIST. (eds) Garba SA, Ijagbone IF Iyagba AO, Iyamu AO, Kiliani AS, Ufaruna N, 2000: 141-146.
 16. Idowu TO, Iwalewa EO, Aderogba MA, Akinpelu BA, Ogundaini AO. Biochemical and behavioural effects of eleagnine from *Chrysophyllum albidum* J. Biol. Sci 2006; 6:1029-1034.
 17. Idowu TO, Onawunmi GO, Ogundaini AO, Adesanya SA. Antimicrobial constituents of *Chrysophyllum albidum* seed cotyledons. Nigerian Journal of Natural Products and Medicine 2003; 7:33-36.
 18. Adebayo AH, Abolaji AO, Opata TK, Adegbenro IK. Effects of ethanolic leaf extract of *Chrysophyllum albidum* G. on biochemical and haematological parameters of albino Wistar rats. African Journal of Biotechnology 2010; 9 (14): 2145-2150.
 19. Idaguko CA, Oremosu AA, Duru FIO, Awopetu PI. Protective Effect of Ethanolic Leaf Extract of *Chrysophyllum albidum* (Sapotaceae G. Don) on Histological Changes in the Pancreas of Streptozotocin-induced Diabetic Sprague Dawley Rats. JAnat. Sci 2018; 9(1): 1-6.
 20. Onyeka CA, Aligwekwe AU, Olawuyi TS, Nwakanma AA, Kalu EC, Oyeyemi AW. Antifertility effects of ethanolic root bark extract of *Chrysophyllum albidum* in male albino rats. Int J Appl Res Nat Prod 2012; 5(1): 12-17.
 21. Oigbochie EV, Omega K, Odiase ED. Aqueous root extract of *Chrysophyllum albidum* caused dose and duration dependent increases in some reproductive hormones and spermatogenic arrest in the testes of male Wistar rats. Clinical Phytoscience 2019; 5(1):3.
 22. Institute for Laboratory Animal Research. Guide for the Care and Use of Laboratory Animals. 8th Ed. pg. 15. (National Academies Press, Washington, DC, 2011).
 23. Idaguko CA, Duru FIO, Oremosu AA. Antioxidant, hypolipidemic and Hypoglycemic Effect of Ethanol Leaf Extract of *Chrysophyllum albidum* on Streptozotocin- Induced Diabetic Rats. JAnat Sci 2017; 8 (1): 67-73
 24. Lorke D. A new approach to practical acute toxicity testing. Archives of toxicology 1983; 54 (4): 275-287.
 25. Knuth UA, Hull MG, Jacobs HS. Amenorrhoea and loss of weight. BJOG: An International Journal of Obstetrics and Gynaecology 1977; 84 (11): 801-807.
 26. Onyeka CA, Fabunmi OO, Aligwekwe AU, Ofoego UC, Leko B, Anthony OA. Ethanolic Leaf Extract of *Chrysophyllum albidum* on sperm analysis, hormonal profile, SOD and testicular histology of adult male wistar rats. Agric. Biol. J. N. Am., 2013, 4(3): 160-165
 27. Ashafa AO, Yakubu MT, Grierson DS, Afolayan AJ. Effects of aqueous extract from the leaves of *Chrysocoma ciliata* L. on some biochemical parameters of Wistar rats. African Journal of Biotechnology 2009; 8 (8): 1425-1430
 28. Yakubu MT, Akanji MA, Oladiji AT. Aphrodisiac potentials of the aqueous extract of *Fadogia agrestis* (Schweinf. Ex Hiern) stem in male albino rats. Asian Journal of Andrology 2005; 7 (4):399-404.
 29. Egba SI, Udom IU, Okonkwo CO. “The most common causes of female infertility are hormones” Global Journal of Biochemistry and Biotechnology 2014; 9 (1): 24-29.
 30. Oladipupo AA, Oladipupo TG. Phytochemical analysis and antimicrobial effect of *Chrysophyllum albidum* leave extract on gastrointestinal tract pathogenic bacteria and fungi in human. Journal of Applied Chemistry 2014; 7:1-5.
 31. Al-Qarawi AA, Abdel-Rahman HA, El-Badry AA, Harraz F, Razig NA, Abdel-Magied EM. The effect of extracts of *Cynomorium coccineum* and *Withania somnifera* on gonadotrophins and ovarian follicles of immature Wistar rats. Phytotherapy Research 2000; 14 (4): 288-290.
 32. Solomon T, Largesse Z, Mekbeb A, Eyasu M, Asfaw D. Effect of *Rumex steudelii* methanolic root extract on ovarian folliculogenesis and uterine histology in female albino rats. African health sciences 2010; 10 (4): 353-361
 33. Hummizsch K, Irving-Rodgers HF, Schwartz J, Rodgers RJ. Development of the mammalian ovary and follicles. In: The ovary (3rd Ed) 2019 (pp. 71-82). Academic Press.
 34. Moenter SM, Brand RC, Karsch FJ. Dynamics of gonadotropin-releasing hormone (GnRH) secretion during the GnRH surge: insights into the mechanism of GnRH surge induction.

- Endocrinology 1992; 130 (5): 2978-84.
35. Navarro FK, Navarro RD, Murgas LD, Pereira MA, Hundley GC. Plasma levels of luteinizing hormone and gonadal maturation of lambari females under different photoperiods. *Pesquisa Agropecuária Brasileira* 2013; 48 (8):1064-1070.
 36. Devesa J, Caicedo D. The role of growth hormone on ovarian functioning and ovarian angiogenesis. *Frontiers in endocrinology* 2019; 10:450.
 37. Kumar P, Sait SF. Luteinizing hormone and its dilemma in ovulation induction. *Journal of human reproductive sciences*. 2011; 4 (1): 2-7.
 38. Filicori M, Cognigni GE, Samara A, Melappioni S, Perri T, Cantelli B, Parmegiani L, Pelusi G, DeAloysio D. The use of LH activity to drive folliculogenesis: exploring uncharted territories in ovulation induction. *Human Reproduction Update* 2002; 8 (6): 543-57.
 39. Yakubu MT, Akanji MA, Oladiji AT, Olatinwo AO, Adesokan AA, Yakubu MO, Owoyele BV, Sunmonu TO, Ajao MS. Effect of *Cnidioscolous aconitifolius* (Miller) IM Johnston leaf extract on reproductive hormones of female rats. *Iranian Journal of Reproductive Medicine* 2008; 6 (3): 149-155.
 40. Micevych PE, Sinchak K. The neurosteroid progesterone underlies estrogen positive feedback of the LH surge. *Frontiers in endocrinology* 2011; 2:90.
 41. Billig H, Furuta IT, Hsueh AJ. Estrogens inhibit and androgens enhance ovarian granulosa cell apoptosis. *Endocrinology* 1993; 133 (5): 2204-12.
 42. McGee EA, Hsueh AJ. Initial and cyclic recruitment of ovarian follicles. *Endocrine reviews* 2000; 21 (2): 200-214.
 43. Lucidi P, Bernabò N, Turriani M, Barboni B, Mattioli M. Cumulus cells steroidogenesis is influenced by the degree of oocyte maturation. *Reproductive Biology and Endocrinology* 2003; 1 (1): 45-55.